



Ultrasound Cases - Pancreas

Wendy Blount, DVM

Kooper



10 yr CM Miniature Schnauzer

•CC: anorexia, vomiting and weight loss

—6 weeks duration

—No response to treatment with IV fluids, metoclopramide, antibiotics, mirtazapine

—Another similar episode 3 months ago responded well to same treatment

•Exam: BCS 4/9, temp 103.1°F, pain on palpation of the cranial abdomen, dehydrated 5%

Kooper



•CBC: neutrophilia 17,300/ul


•profile: albumin 2.1 g/dl, ALP 1105 U/L, ALT 984 U/L, bili 1.3 mg/dl, Ca⁺⁺ 7.9 mg/dl, serum is lipemic 3+

•UA: proteinuria 2+

•cPL: abnormal

•Abdominal Ultrasound:

Kooper



•CBC:

•profile

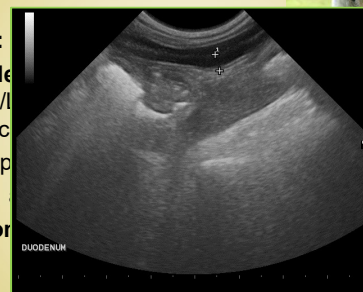
984 U/L

lipemic


•UA: p

•cPL:

•Abdom



Kooper



•CBC:

•profil

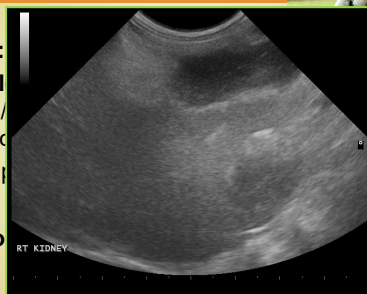984 U/L

lipemic

•UA: p

•cPL:

•Abdo



Kooper



•CBC

•prof

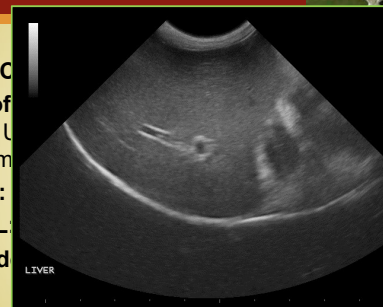
984 U/L

lipem

•UA:



•cPL:

•Abdo




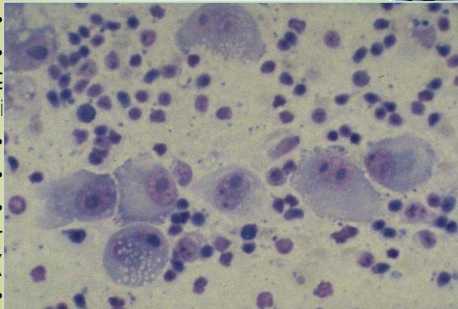
Kooper

- CBC:
- profil
984 U
- lipemi
- UA:
- cPL:
- Abdo




T
is

Kooper




is
atic

Kooper



- CBC:** neutrophilia 17,300/ul
- profile:** albumin 2.1 g/dl, ALP 1105 U/L, ALT 984 U/L, bili 1.3 mg/dl, Ca⁺⁺ 7.9 mg/dl, serum is lipemic 3+
- UA:** proteinuria 2+
- cPL:** abnormal
- Abdominal Ultrasound:** pancreatitis, pancreatic masses, stomach 1-2 contractions per minute (hypomotile)
- FNA:** carcinoma, presumed pancreatic
- Outcome:** Kooper euthanized 3 weeks later

Lessons from Kooper



- Pancreatic carcinoma often presents as pancreatitis unresponsive to therapy
- Ultrasound at the onset of treatment for pancreatic is advisable
 - evaluates for disease that might confound successful treatment, including pancreatic cancer
- Prognosis for pancreatic carcinoma is dismal

GI Hypomotility

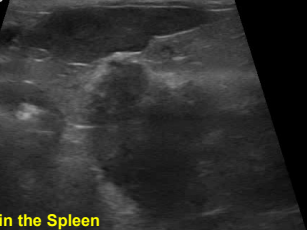
- Bowel obstruction
- Gastric ulcers
- Severe pancreatitis
- Inflammatory bowel disease
- GI neoplasia
- Peritonitis
- Post-operative ileus (abdominal surgery)

Most common cause of hypomotility is acute GI obstruction (FB, neoplasia, mass)

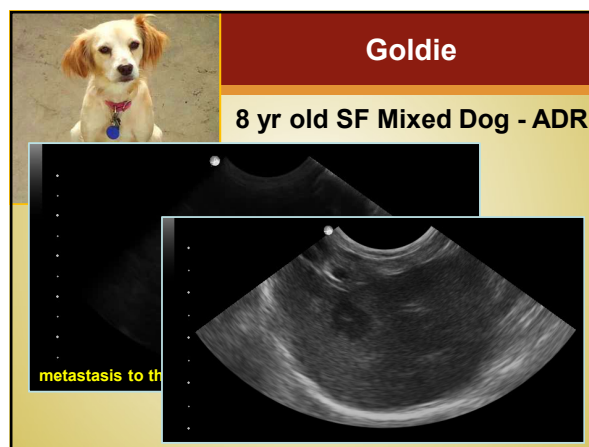
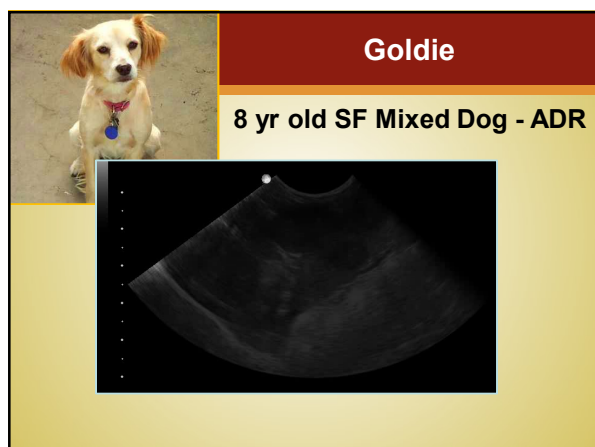
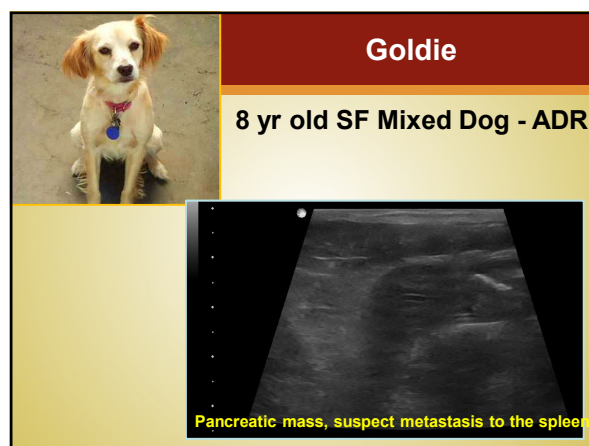
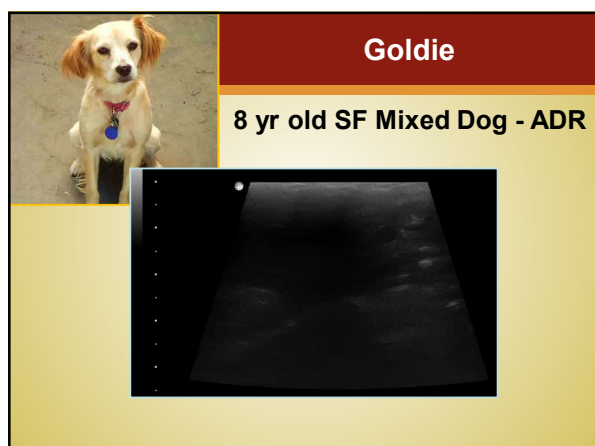Goldie

8 yr old SF Mixed Dog - ADR



Target Lesions in the Spleen
glimpse of another deeper mass



Jessie

10 yr SF Lab Ret

Hx: moved to TX last year, dog has trouble with blood sugar and was diagnosed with insulinoma 2 yrs ago. Right now, doing well on 5 meals a day and 5mg pred daily

- New TexasVet doesn't think Jessie has insulinoma, because she would be dead by now. When they try to wean off prednisone, she crashes (glu 30-40)

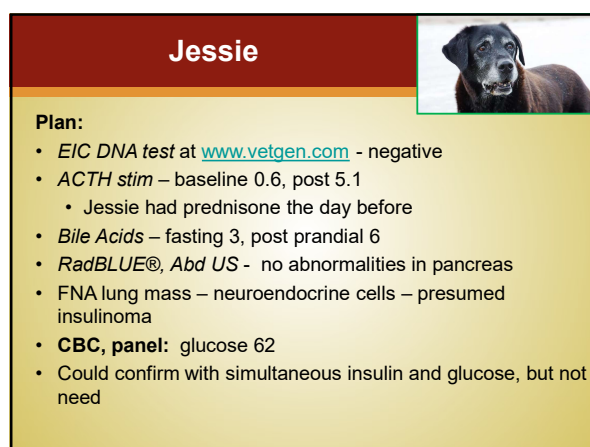
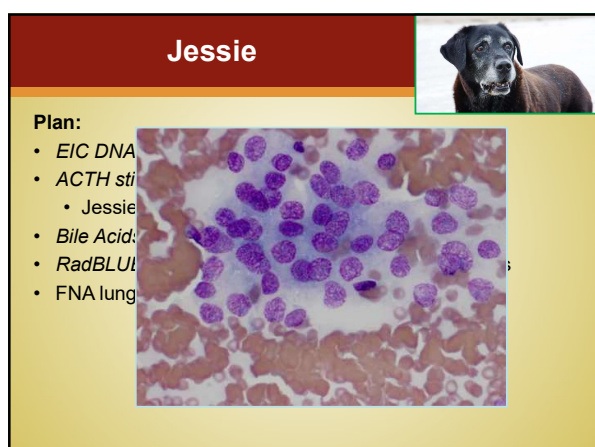
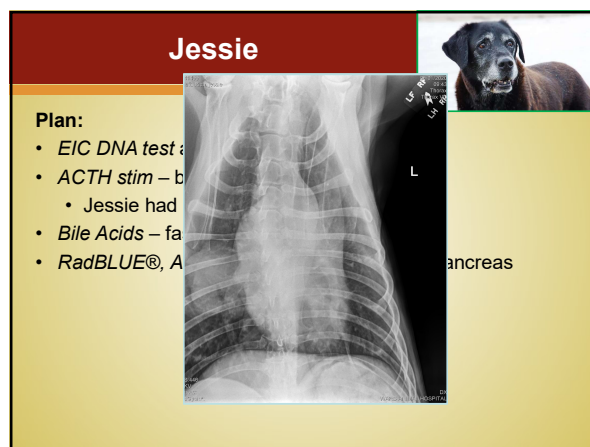
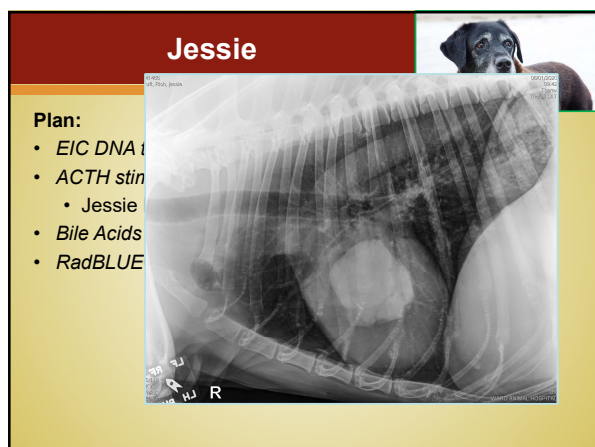
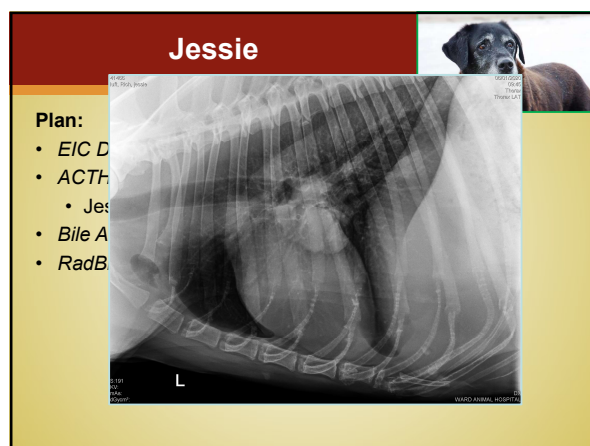
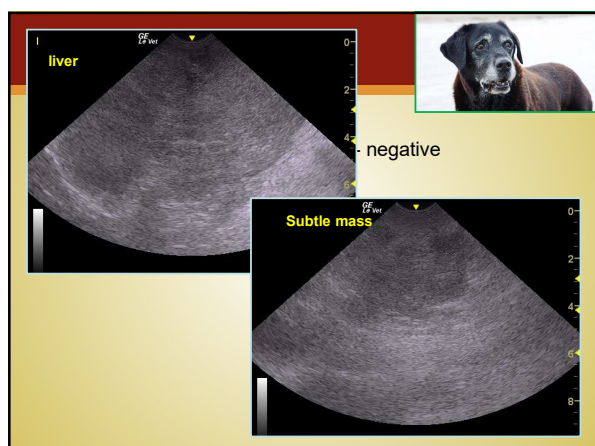
DDx: long term episodic hypoglycemia

- Exercise induce collapse of Lab Ret (EIC)
- Atypical Hypoadrenocorticism
- Severe liver disease
- Insulinoma, hepatic tumor or other neoplasia

Jessie

Plan:

- EIC DNA test at www.vetgen.com - negative
- ACTH stim – baseline 0.6, post 5.1
 - Jessie had prednisone the day before
- Bile Acids – fasting 3, post prandial 6
- RadBLUE®, Abd US -



Summary

- PowerPoints -[Pancreas Ultrasound Cases](#)
- .pdf of PowerPoint -[Pancreas Ultrasound Cases](#)

Acknowledgements

- Eastex Vet Clinic - Nacogdoches TX - Kooper
- Southwood Drive Animal Clinic - Lufkin TX - Goldie