



Ultrasound Cases - Pancreas

Wendy Blount, DVM

Kooper



10 yr CM Miniature Schnauzer

- CC:** anorexia, vomiting and weight loss
 - 6 weeks duration
 - No response to treatment with IV fluids, metoclopramide, antibiotics, mirtazapine
 - Another similar episode 3 months ago responded well to same treatment
- Exam:** BCS 4/9, temp 103.1°F, pain on palpation of the cranial abdomen, dehydrated 5%

Kooper



- CBC:** neutrophilia 17,300/uI
- profile:** albumin 2.1 g/dl, ALP 1105 U/L, ALT 984 U/L, bili 1.3 mg/dl, Ca⁺⁺ 7.9 mg/dl, serum is lipemic 3+
- UA:** proteinuria 2+
- cPL:** abnormal
- Abdominal Ultrasound:**

SIEMENS

EASTEX VETERINARY CLINIC

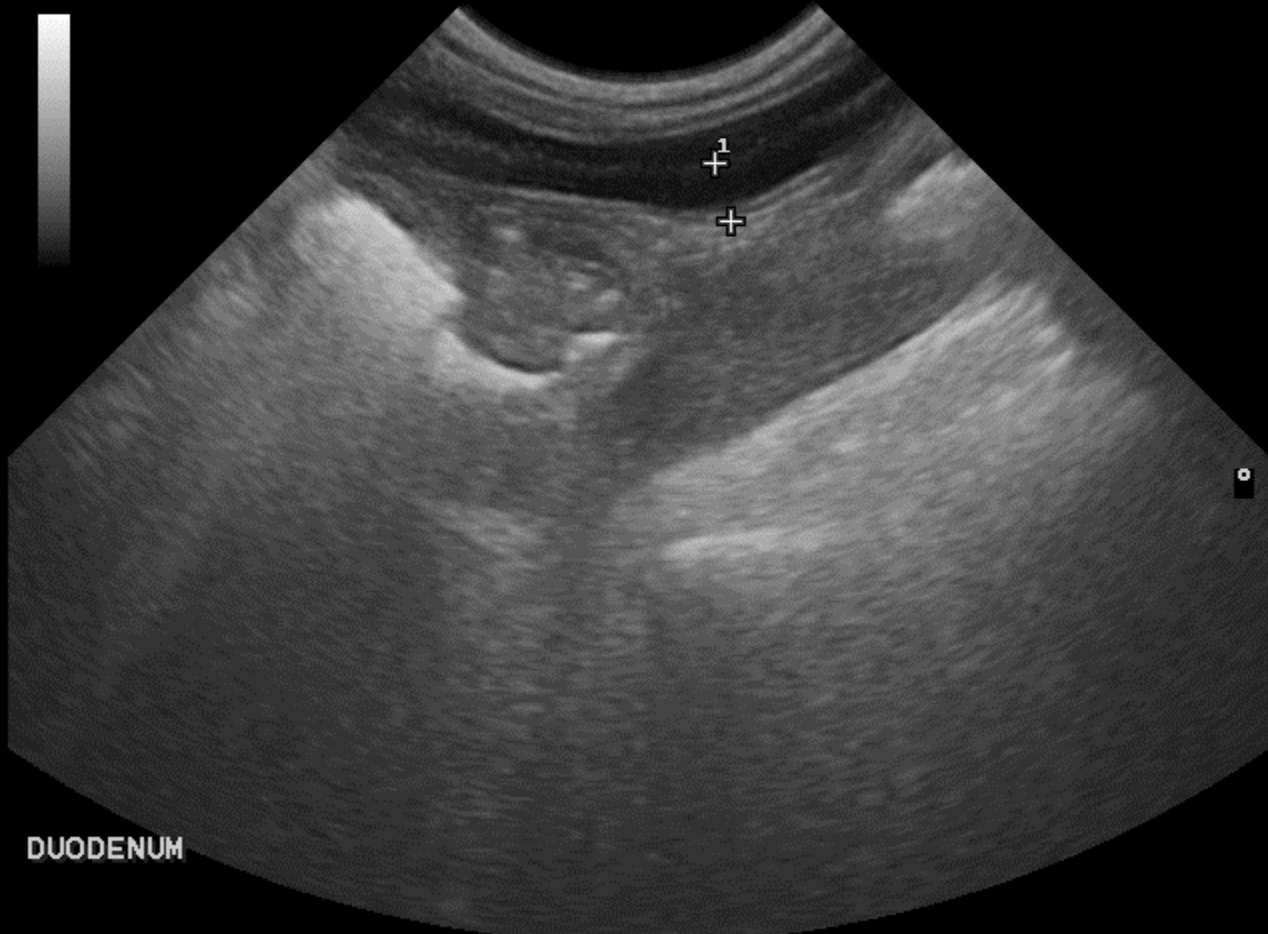
BALLARD, KELLY, ID: COOPER,

SEP 28 2015 11:55am

B	F	8.0	MHZ	G	52%
D	6	cm	XV	C	
PRC	15-2-H	PRS	3		
PST	3	MV	3		

SM A VET CA123

D1 0.38 cm



DUODENUM

SIEMENS

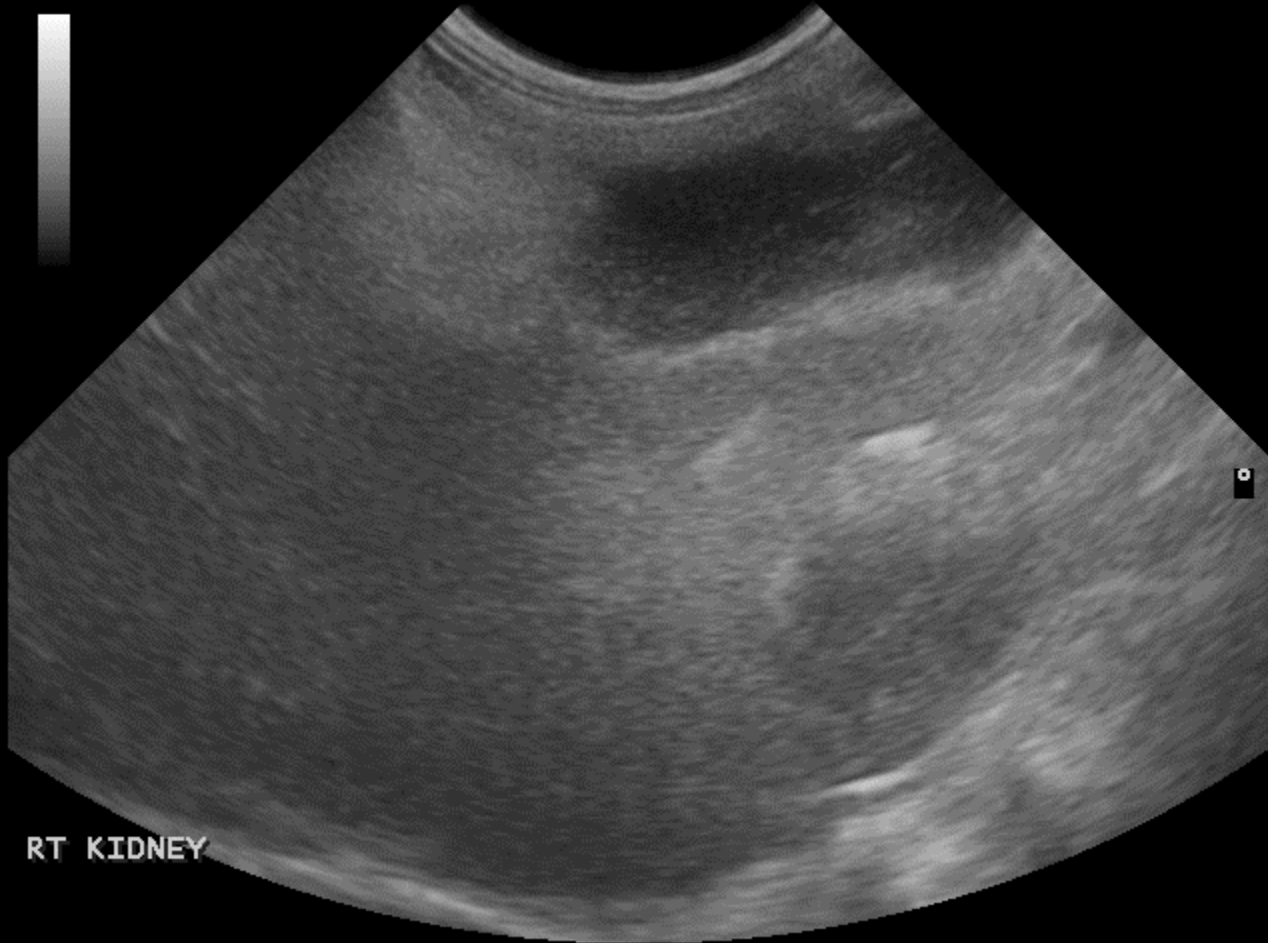
EASTEX VETERINARY CLINIC

BALLARD, KELLY, ID: COOPER,

SEP 28 2015 11:56am

B	F	8.0	MHz	G	52%
D		6	cm	XV	C
PRC		15-2-H		PRS	3
PST		3		MV	3

SM A VET CA123



RT KIDNEY

SIEMENS

EASTEX VETERINARY CLINIC

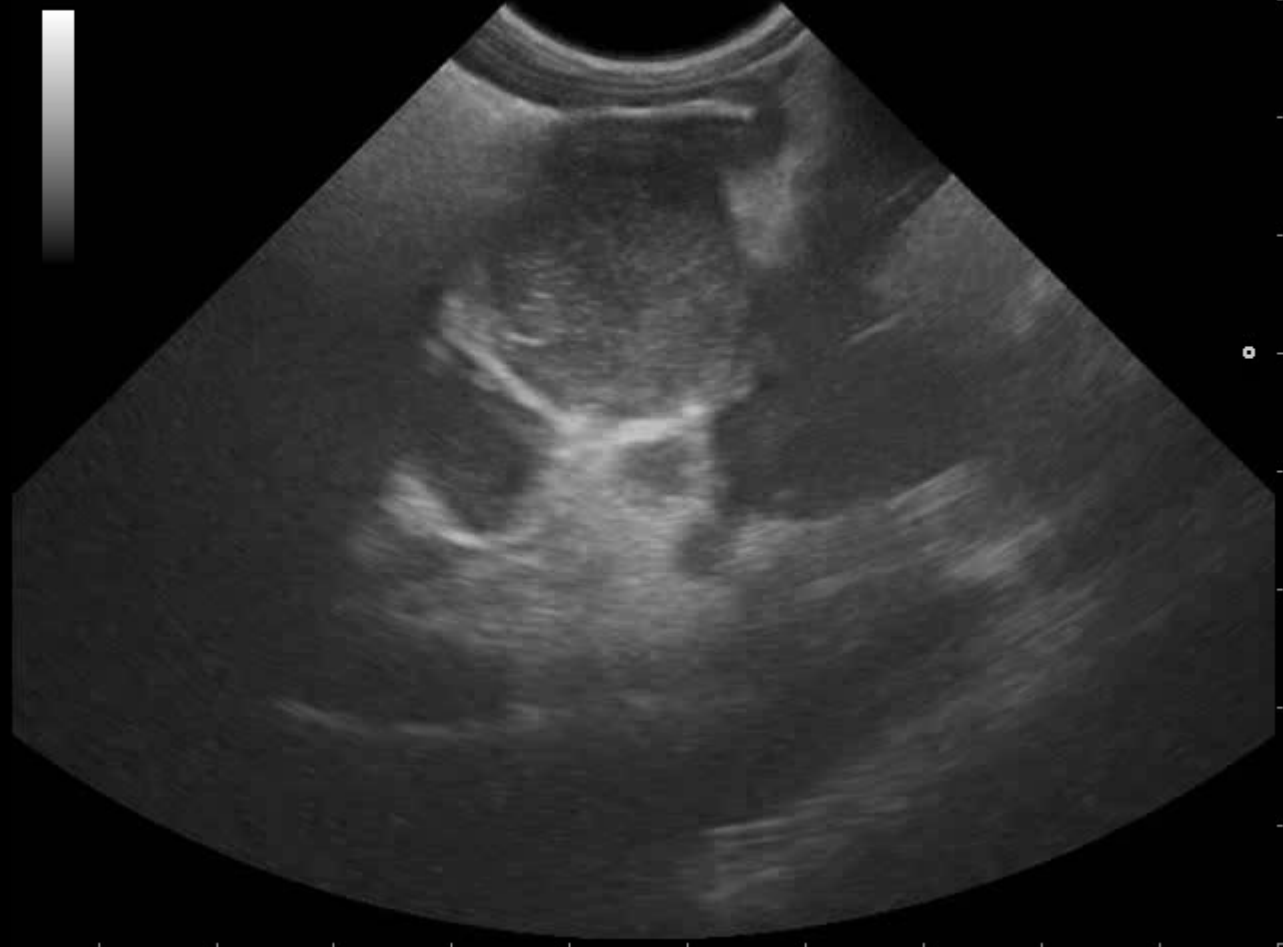
BALLARD, KELLY, ID: COOPER,

SEP 28 2015 11:52am

B	F	8.0	MHz	G	52%
D	8	cm	XV	C	
PRC	15-2-H	PRS	3		
PST	3	MV	3		

0:00:00.31

SM A VET CA123



SIEMENS

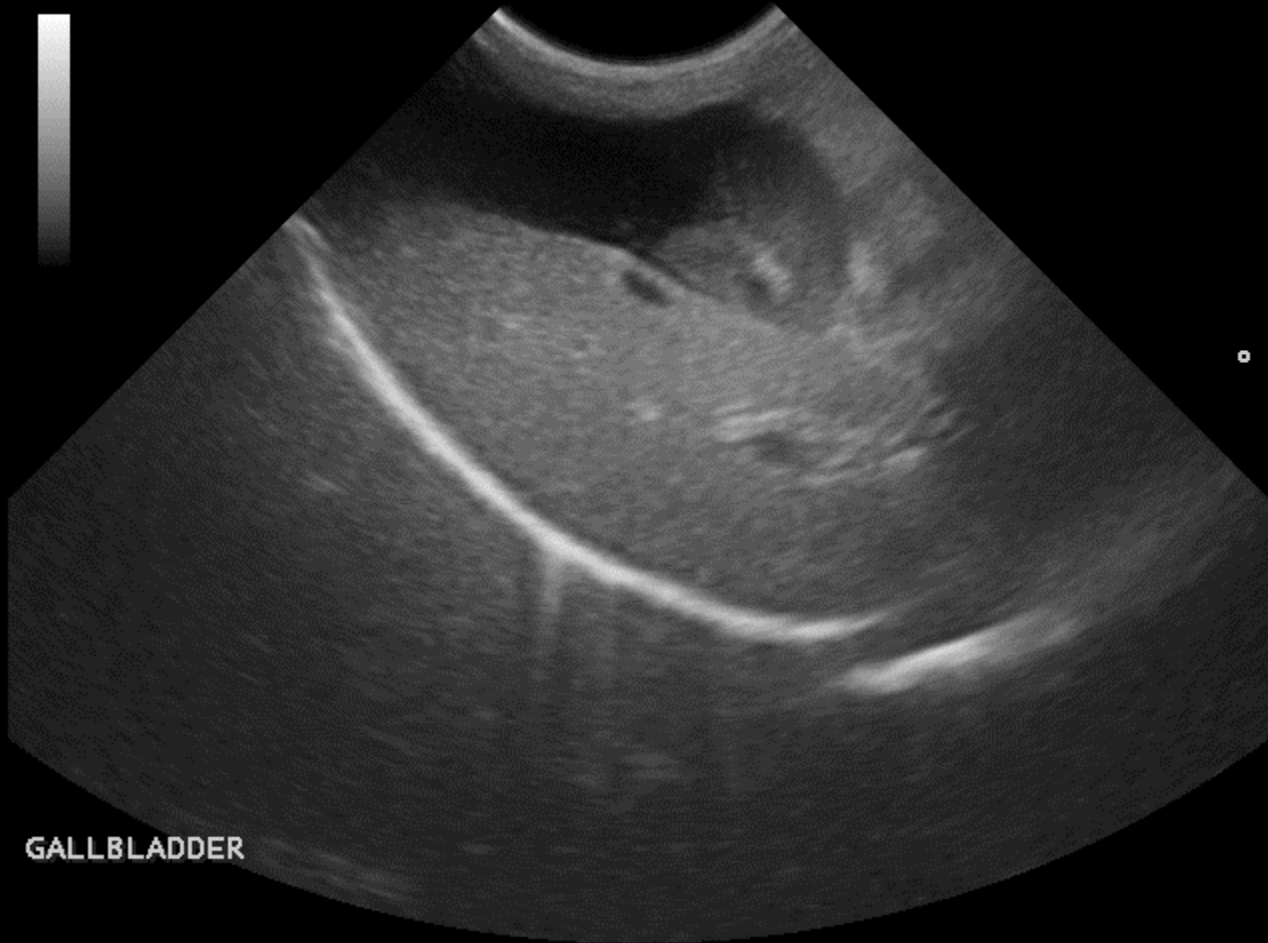
EASTEX VETERINARY CLINIC

BALLARD, KELLY, ID: COOPER,

SEP 28 2015 11:51am

B	F	8.0	MHz	G	52%
D		8	cm	XV	C
PRC		15-2-H		PRS	3
PST		3		MV	3

SM A VET CA123



GALLBLADDER

SIEMENS

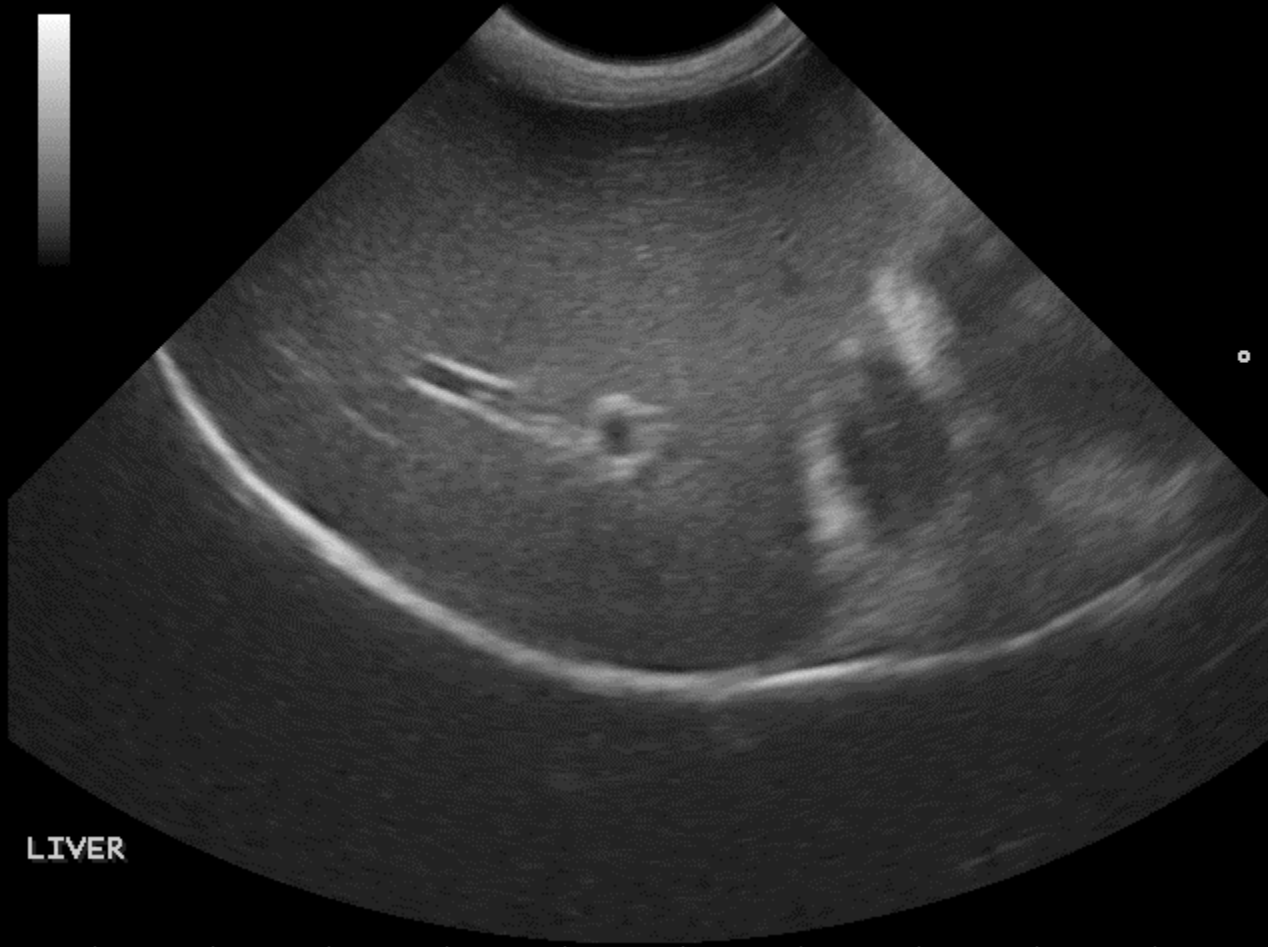
EASTEX VETERINARY CLINIC

BALLARD, KELLY, ID: COOPER,

SEP 28 2015 11:51am

B	F	8.0	MHz	G	52%
D		8	cm	XV	C
PRC		15-2-H		PRS	3
PST		3		MV	3

SM A VET CA123



LIVER

Kooper



- CBC:** neutrophilia 17,300/ul
- profile:** albumin 2.1 g/dl, ALP 1105 U/L, ALT 984 U/L, bili 1.3 mg/dl, Ca⁺⁺ 7.9 mg/dl, serum is lipemic 3+
- UA:** proteinuria 2+
- cPL:** abnormal
- Abdominal Ultrasound:** pancreatitis, pancreatic masses, multiple hepatic masses, stomach 1-2 contractions per minute (hypomotile)
- FNA:** carcinoma, presumed pancreatic
- Outcome:** Kooper euthanized 3 weeks later

Lessons from Kooper



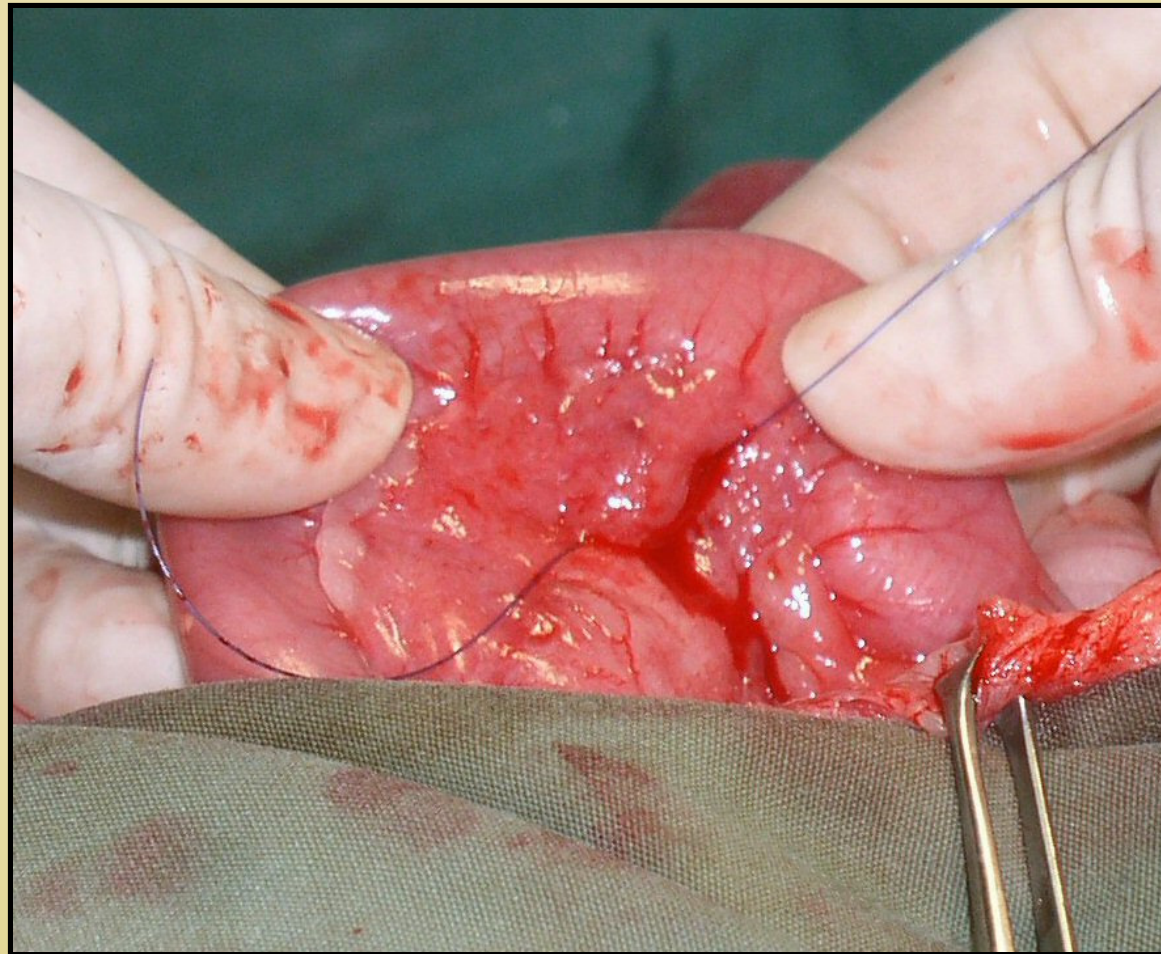
- Pancreatic carcinoma often presents as pancreatitis unresponsive to therapy
- Ultrasound at the onset of treatment for pancreatic is advisable
 - evaluates for disease that might confound successful treatment, including pancreatic cancer
- Prognosis for pancreatic carcinoma is dismal

GI Hypomotility

- Bowel obstruction
- Gastric ulcers
- Severe pancreatitis
- Inflammatory bowel disease
- GI neoplasia
- Peritonitis
- Post-operative ileus (abdominal surgery)

Most common cause of hypermotility is acute GI obstruction (FB, neoplasia, mass)

Pancreatic Biopsy



Pancreatic Biopsy

