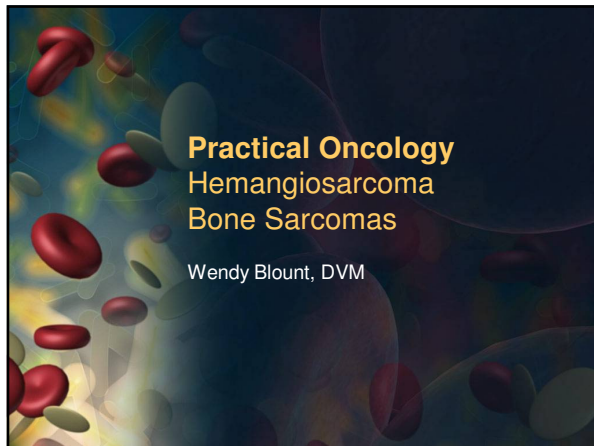

Hemangiosarcoma

- Highly malignant neoplasm
- Arise most often from spleen, liver, right atrium, and subcutaneous tissues
- Can be anywhere one might find a blood vessel
- 25% have lesions in the spleen and the right atrium at the time of diagnosis
- Dermal HSA is a different animal
 - Comes from sun exposure
 - Behaves more benignly
- Almost always has already metastasized at the time of diagnosis
- Death is usually by hemorrhage

Hemangiosarcoma

Clinical Signs

- Abdominal Bleeding
 - ascites
 - Weakness, pallor, shock
 - Palpable Abdominal Mass
- Pericardial Effusion (occasionally thoracic)
 - Dyspnea with muffled heart sounds
 - Gigantenormous heart on radiographs
 - Coughing
 - Weakness, pallor, shock
 - Electrical alternans on ECG

Hemangiosarcoma


Diagnosis


- Many oncologists condone fine needle aspiration of abdominal masses
- Aspiration of peripheral masses often yields blood only
- Doing so increases risk of hemorrhage
- I prefer diagnostic surgery with splenectomy if no evidence of metastasis evident
- Biopsying metastatic abdominal lesions increases propensity to bleed
- I prefer histopathology for diagnosis
- 50% of bleeding splenic masses in young dogs are HSA
- 75-80% of bleeding splenic masses in older dogs are HSA

Hemangiosarcoma

Treatment

- Evaluate for propensity to bleed and metastasis prior to considering treatment
- CBC, platelet count
- PT, PTT if possible
- Thoracic radiographs (3 views)
- Abdominal ultrasound
- Echocardiogram
 - Check for mass in right atrium and pleural effusion
- Thoracic radiographs and abdominal ultrasound every 6-8 weeks






Hemangiosarcoma

Radiation


- Only local control for a localized mass
- Bulky subcutaneous or muscular masses
- Palliative – to relieve pain and mediate symptoms
- When there is no suspected propensity to bleed
- Adjuvant chemotherapy is advisable
- Median survival 95 days



Hemangiosarcoma

Surgery

- Splenectomy or right auriculectomy to stop acute hemorrhage
- More likely to be helpful if no thoracic mets
- Debulking is not usually recommended
- Manage DIC
- Discuss possibility of euthanasia on the table or shortly thereafter if remaining propensity to bleed is identified on surgery
- Median survival with splenectomy only is 60-70 days
- Median survival right auriculectomy 90-150 days




Hemangiosarcoma

Transfusion

- To prevent death due to exsanguination
- To manage DIC
- To minimize anesthesia risk
- Whole fresh blood is best


Surgery and chemo gives the longest survival times – doxorubicin x5
 More myelosuppressive protocols may be more efficacious, but side effects are considerable
 Median survival 3-7 months



Osteosarcoma

Clinical Signs


- Lameness in a giant breed dog
- “Toward the knee” and “away from the elbow”
- Some evidence that metal implants may increase risk
- Possible increased risk for sterilized animals as compared to sexually intact



Osteosarcoma

Diagnosis

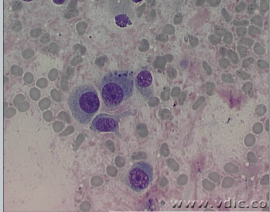
- Cytology taken with 18g needle can be diagnostic
- If not, sedate and take radiograph guided biopsy of the lytic bony mass
- Do not amputate without biopsy
 - DDx fungal osteomyelitis
 - DDx metastatic carcinoma
- Abdominal ultrasound is a low yield test for OSA, but a reasonable test for fungal infection and carcinoma
 - FNA of liver and spleen can reveal systemic mycosis



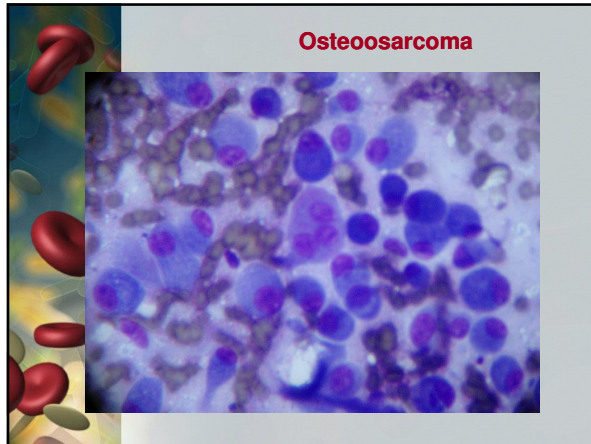
Osteosarcoma

Diagnosis

- Osteoblasts (“flag cells”)
- Osteoclasts (multinucleate giant cells)
- Mesenchymal cells



www.vdic.co



Osteosarcoma

Osteosarcoma

Amputation

- Amputation provides pain relief, but almost all have already metastasized
- Surgery alone improves quality of life, but does not prolong survival
- May not be indicated for dogs with pulmonary metastasis
- Median survival 4 months
- 10% of dogs are alive at one year
- Mobility issues should be considered
- Large dogs can have difficulty ambulating without a front limb
- Orthopedic problems in remaining limbs can be exacerbated
- Radiograph all 4 limbs prior to amputation

Osteosarcoma

Limb Sparing Surgery

- Reasonable option only for relatively small lesions in the distal radius
- Function is poor for the other 3 locations
- Tumors involving more than 50% of bone or those that invade soft tissue in any location have poor mobility
- CT reveals that tumor is often larger than it appears on radiographs

Osteosarcoma

Palliative Radiation

- Once weekly for three weeks
- 75% have significant clinical improvement in lameness and pain score
- Median pain relief is 2 months
- Increased mobility may increase risk of pathologic fracture (?)

Osteosarcoma


Chemotherapy

- lengthens survival significantly following amputation
- doxorubicin q3 weeks x 5
 - Get a baseline echocardiogram
- Or carboplatin q3 weeks x 5
- Cisplatin or cisplatin + doxorubicin are equally effective, but much more toxic
- Chemotherapy should begin 2 weeks after surgery

Osteosarcoma

Prognosis

- Median survival 4 months with amputation only
- Median survival 6-16 months with amputation and chemo
- 10% alive in 1 year with amputation alone
- 30-62% alive in 1 year with both
- 2 year survival is 7-21% with amputation and chemo
- Dogs almost never survive to 2 years with amputation alone



Osteosarcoma


Prognosis

- Those with thoracic metastasis at the **time of diagnosis do poorly no matter how treated**
- Elevated SAP
 - Median survival 5.5 months if SAP elevated
 - Median survival 12.5 months if SAP within normal range
- High grade tumors have worse prognosis
- Dogs between 7-10 years of age do the best
 - Young and older dogs don't fare as well
- Dogs with elevated lymphocytes and/or monocytes do not do as well
- Advances in the last 20 years have led to increase in survival by 500%



Client Handouts


- [Hemangiosarcoma](#)
- [Osteosarcoma](#)
- [Yunnan Pai Yao](#)



Yunnan Pai Yao

Other names for this Chinese Herb

- Yun(n)an Bai Yao
- Yun(n)an Paiyao
- Yun(n)an Baiyou
- Yun(n)an Paiyou
- Yun(n)an Payao
- Yun(n)an Piao
- Yun(n)an Paiao
- Hun(n)an Paiyao




Yunnan Pai Yao

Uses

- stop bleeding
- (promote wound healing)
- (relieve pain)

Scientific support

- shortened clotting time within 30 minutes after oral administration in rabbits
- effects lasted for 4 hours (Ogle, 1977).
- Decreased clotting times in rabbit and human blood (Ogle 1976), and bovine blood (Monke 2000).



Yunnan Pai Yao

Safety

- has been given to thousands of dogs over several decades by veterinarians who practice CAVM, with no reported adverse effects (Ogle 1977).

Protocol

- Used orally and topically
- Dosage table in the handout
- Ordering information in the handout

