



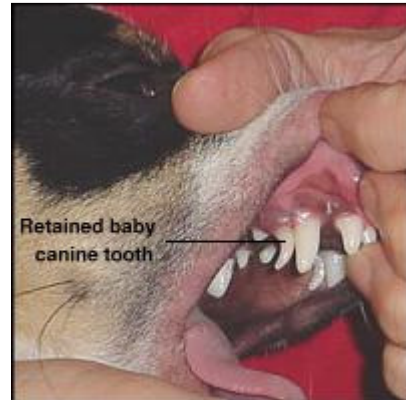Dental Anatomy of Dogs

Dogs are carnivores and have teeth that reflect their meat-eating evolutionary history. Pet dogs, of course, have been turned into omnivores, as most dry dog foods contain substantial amounts of plant material.

The dog shown to the right - Lakota the Alaskan husky - might appear to be vicious, but he's actually having lots of fun snarling while playing tug-of-war with a companion. Unless you know the dog, snarling should be interpreted as a warning of potentially aggressive behavior. Some dogs show a related behavior called "smiling", which is typically a submissive signal and usually associated with tail-wagging.



A common abnormality in canine dentition is retention of deciduous (baby) teeth. This occurs when the permanent tooth bud does not grow immediately beneath the deciduous tooth, and therefore does not cause the roots of the deciduous tooth to be resorbed. Sparky dog - pictured to the right - has retained canine teeth (the small, more pointed teeth immediately behind his permanent canines). If a retained tooth causes the permanent tooth to erupt in an abnormal position or causes other types of problems, it should be extracted. *Picture graciously provided by Ardena Ellard.*



Dental Formulae

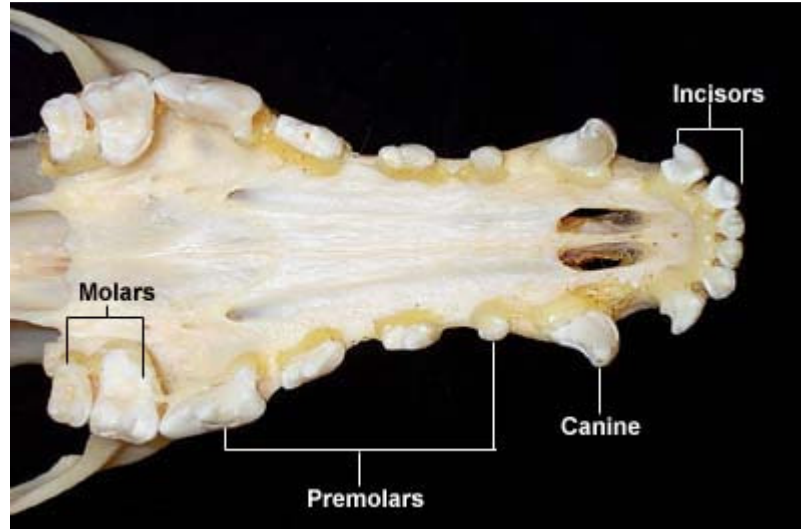
Deciduous	$\frac{3 \ 1 \ 3}{3 \ 1 \ 3}$	= 14	Permanent	$\frac{3 \ 1 \ 4 \ 2}{3 \ 1 \ 4 \ 3}$	= 21
------------------	-------------------------------	------	------------------	---------------------------------------	------

Note: P⁴ and M₁ are the carnasial or shearing teeth

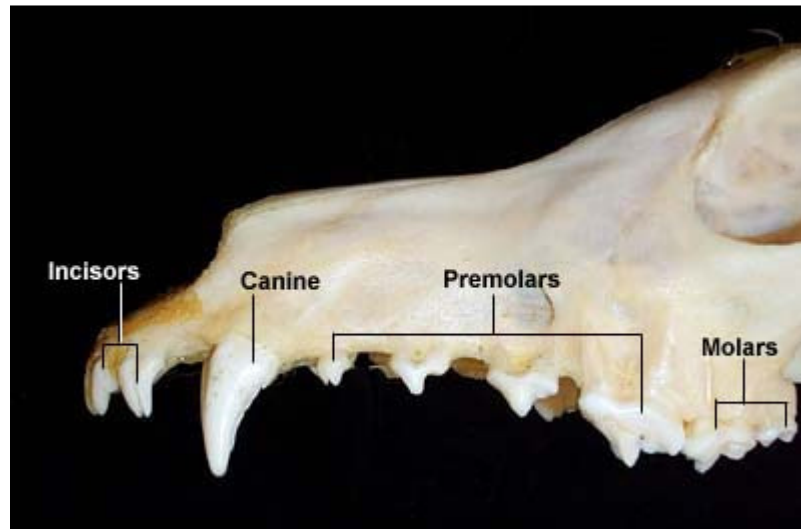
Tooth Eruption

	Deciduous	Permanent
Incisors	4 - 6 weeks	3 - 5 months
Canine	5 - 6 weeks	4 - 6 months
Premolars	6 weeks	4 - 5 months
Molars		5 - 7 months

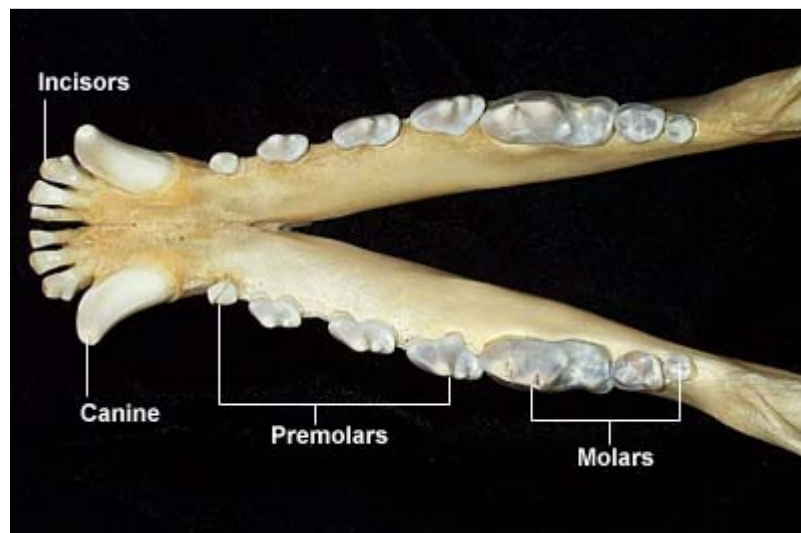
Maxillary Arcade



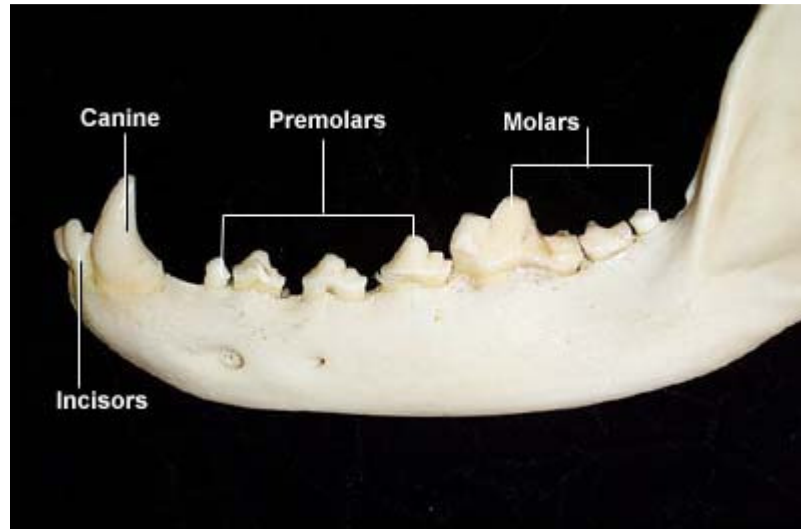
**Maxillary Arcade
(lateral view)**



Mandibular Arcade



Mandibular Arcade
(lateral view)



Index of: [Dental Anatomy](#)

Last updated on January 3, 2003

Author: Melissa Rouge

Send comments [via form](#) or email to rbowen@colostate.edu