



# Dental Anatomy of Cats

Cats are obligate carnivores, although pet cats consume a lot of plant material if they are fed dry cat food. None of the teeth of cats, including their molars, have grinding surfaces; they clearly evolved to eat "meat". [Dogs](#) also are carnivores, but do have grinding surfaces on their molar teeth.

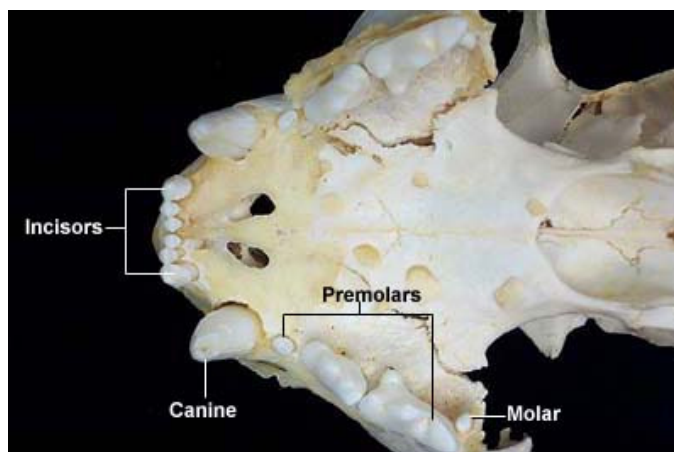


Dental Formulae			
<b>Deciduous</b>	$\frac{3 \ 1 \ 3}{3 \ 1 \ 2}$	= 13	
<b>Permanent</b>	$\frac{3 \ 1 \ 3 \ 1}{3 \ 1 \ 2 \ 1}$	= 15	

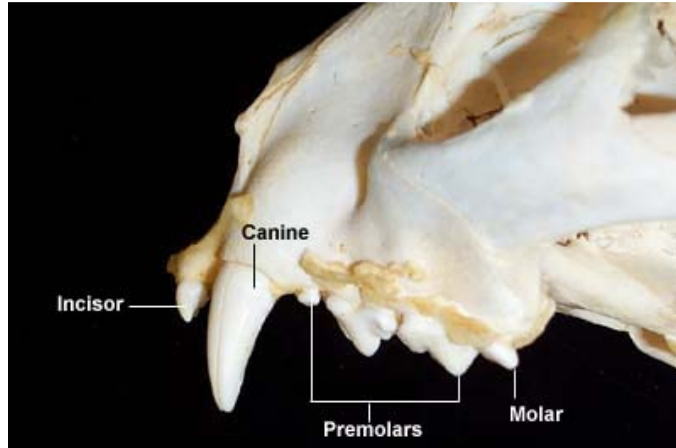
Tooth Eruption		
	Deciduous	Permanent
<b>Incisors</b>	3 - 4 weeks	3.5 - 5.5 months
<b>Canine</b>	3 - 4 weeks	5.5 - 6.5 months
<b>Premolars</b>	6 weeks	4 - 5 months
<b>Molars</b>		5 - 6 months

The following images demonstrate feline dental anatomy using the skull of a mountain lion. Mountain lions have the same dental formula as domestic cats.

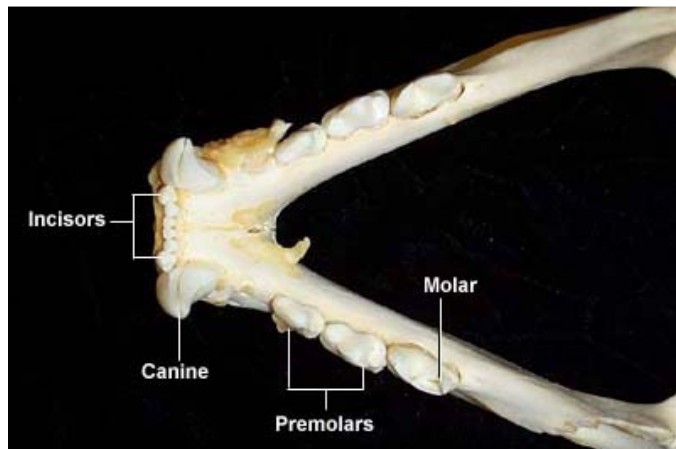
Maxillary Arcade



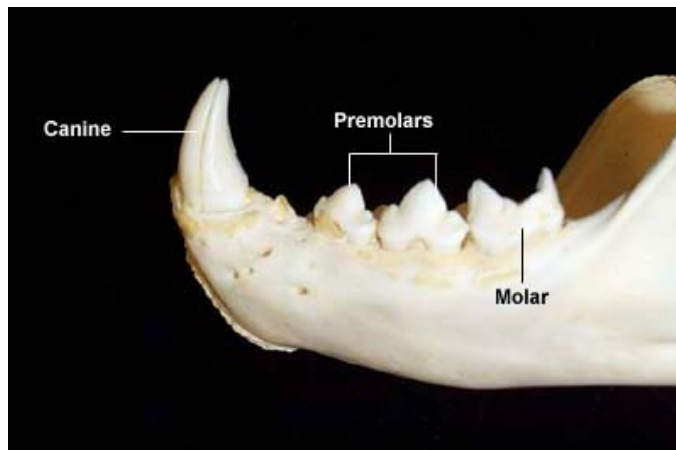
**Maxillary Arcade**  
(Lateral View)



**Mandibular Arcade**



**Mandibular Arcade**  
(Lateral View)



---

Index of: [Dental Anatomy](#)

---

Last updated on November 6, 2001, Author: Melissa Rouge